



Delusion of Pregnancy as a Somatic-Type Delusional Disorder in a Young Male From the South of Iran

Reza Bidaki^{1,2}, Bonnie Bozorg³, Mohammad Ayatollahi⁴, Mehrdad Roozbeh^{5*}

¹Research Center of Addiction and Behavioral Sciences, Shahid Sadoughi University of Medical Sciences, Yazd, Iran

²Diabetes Research Center, Shahid Sadoughi University of Medical Sciences, Yazd, Iran

³Tehran University of Medical Sciences, Tehran, Iran

⁴Shahid Sadoughi University of Medical Sciences, Yazd, Iran

⁵Medical Research Committee, Shahid Sadoughi University of Medical Sciences, Yazd, Iran

*Corresponding Author: Mehrdad Roozbeh, Medical Student, Medical Research Committee, Shahid Sadoughi University of Medical Sciences, Yazd, Iran. Tel: +98-3536232005, Email: mehrdadroozbeh@gmail.com

Received November 30, 2017; Accepted April 19, 2018; Online Published May 6, 2018

Abstract

Introduction: Delusion of pregnancy is a bizarre delusion in which one feels s/he is carrying a fetus. The etiology is unknown, but aloneness, masturbation, and stress may precipitate this disorder.

Case Presentation: We introduce a young, single man who has delusions of pregnancy. This type of delusion is not a well-known disorder; based on investigated articles, this type of somatic delusion is rare.

Conclusion: This was a chronic case, the exact cause and development of which was unknown. We suggest this phenomenon as a novel symptom. No similar case was found in the literature.

Keywords: Delusion, Pregnancy, Hypochondriacal

1. Introduction

Delusion of pregnancy is a false and fixed belief with interesting phenomenological symptoms not only in women, but also in men.¹ This delusion presents in a variety of organic conditions.² It can be isolated as a functional condition, such as schizophrenia or mood disorder.³⁻⁵ Delusion of pregnancy is also a special form of hypochondria/somatic delusion.⁶

The exact cause of this disorder is unknown. It is probably initiated by a thought. There is an obsessive-compulsive background. The patient makes inferences from one issue; then, an over-valued idea is formed and eventually turns into a delusion.⁷ We hereby present a case of delusion of pregnancy. This delusion is usually observed in married men, though the current patient was single. Its evolution is questionable. There is much evidence to support the importance of discussing this disorder. This delusion is a false but firm idea that cannot be corrected by reasoning and is resistant to treatment. Which specialist should treat this disorder cannot be indisputably determined.

2. Case Presentation

The patient in this case is a 25-year-old single man who masturbates every day. He comes from Hormozgan province in Iran and has a low socioeconomic status and a

minimal education. The patient believes he is in the second trimester of pregnancy and has a uterus.

He referred to a pharmacist to procure a drug for termination of pregnancy. He was not referred to a psychiatrist anywhere.

The patient thought that, when he masturbated, the semen reversed into a uterine cavity. At first, the patient only thought that he might have a uterus, but this idea later developed into a firm belief. He believed that he had fertilized himself, the embryo had taken shape, and that he could feel its movements (Figure 1). The patient requested an ultrasound be done to prove his theorem. This delusion led to distress, insomnia, and serious dysfunction for the patient, causing him to travel a long way to find expert physicians to confirm his assertion. Unfortunately, because of poor insight and judgment, we could not follow him. There were no psychiatric disorders in his family.

3. Discussion

Delusion means false belief about an external reality upon which the patient insists, even though there is evidence against it. It cannot be corrected by reasoning and is not related to the patient's educational or cultural background. Some types of delusion are bizarre, such as the delusion of pregnancy. In this disorder, a person believes s/he is pregnant. The man in this case did not have any

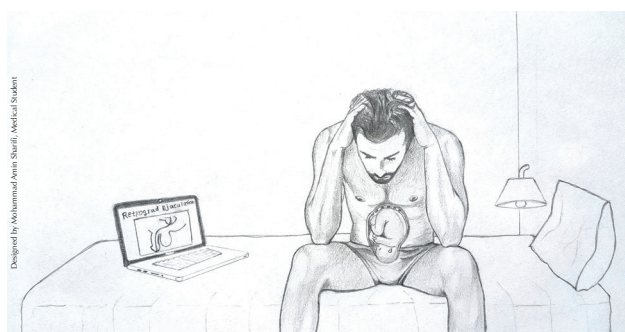


Figure 1. The Man With a Delusion of Pregnancy Due to Retrograde Ejaculation.

homosexual relationships, even though earlier case reports were in contrast to this one.^{6,8} obsessive-compulsive disorder (OCD) or obsessive thoughts may be the initial diagnosis, but the idea is so strange that it is named a delusion. The patient was diagnosed with OCD which is common in this disorder.^{9,10} He had no other medical disorders or history of head trauma. The patient indicated he masturbated often for 10 years. He also reported that after masturbating two months prior to his current visit, he had a retrograde ejaculation, and the semen penetrated his abdominal cavity and caused fertilization. He even sensed the moving fetus in his abdomen and was worried about progressive abdominal distension and delivering the baby. This delusion is so bizarre that the mental status of the patient declined into schizophrenia as this patient is a man and had no abdominal distention to cause a somatic sensation. The defense mechanism known as denial caused this delusion. The patient in this case did masturbate, and thus, semen had been observed. The patient denied this occurrence and tried unconsciously to ignore it. He thought the semen went backward into his abdominal cavity. Another psychodynamic reason for this happening is the tendency of man to get married and have children. This had not happened for this patient, so this delusion was created because of the defense mechanism known as displacement.

4. Conclusion

The patient was diagnosed with somatic-type delusional disorder and was treated with antipsychotic drugs and psychotherapy. This article introduces this case only as a

rare occurrence and not for a treatment plan. The patient did not follow the treatment plan; he had referred only for confirmation. Finally, having the delusion of the presence of a uterus and a pregnancy after masturbation in a young man with no psychiatric history is extremely rare. There is no similar case in the literature.

Authors' Contributions

All authors contributed equally to this Study.

Conflict of Interest Disclosures

The authors declare there are no conflicts of interest with this article.

Ethical Approval

The patient signed a consent form, and the researchers explained the survey to him.

Acknowledgments

The authors thank the patient for his cooperation in this study.

References

1. Manjunatha N, Saddichha S. Delusion of pregnancy associated with antipsychotic induced metabolic syndrome. *World J Biol Psychiatry*. 2009;10(4 Pt 2):669-670. doi:[10.1080/15622970802505800](https://doi.org/10.1080/15622970802505800).
2. Chaturvedi SK. Delusions of pregnancy in men. Case report and review of the literature. *Br J Psychiatry*. 1989;154:716-718. doi:[10.1192/bjp.154.5.716](https://doi.org/10.1192/bjp.154.5.716).
3. Shah JN, Qureshi SU, Jawaid A, Schulz PE. Is there evidence for late cognitive decline in chronic schizophrenia? *Psychiatr Q*. 2012;83(2):127-144. doi:[10.1007/s11126-011-9189-8](https://doi.org/10.1007/s11126-011-9189-8).
4. Bitton G, Thibaut F, Lefevre-Lesage I. Delusions of pregnancy in a man. *Am J Psychiatry*. 1991;148(6):811-812. doi:[10.1176/ajp.148.6.811](https://doi.org/10.1176/ajp.148.6.811).
5. Radhakrishnan R, Satheeshkumar G, Chaturvedi SK. Recurrent delusions of pregnancy in a male. *Psychopathology*. 1999;32(1):1-4. doi:[10.1159/000029059](https://doi.org/10.1159/000029059).
6. Chengappa KNR SS, Brar JS, Keshavan MS. Delusion of pregnancy in men. *Br J Psychiatry*. 1989;155:422-23. doi:[10.1192/bjp.155.3.422b](https://doi.org/10.1192/bjp.155.3.422b).
7. Tarin JJ, Hermenegildo C, Garcia-Perez MA, Cano A. Endocrinology and physiology of pseudocyesis. *Reprod Biol Endocrinol*. 2013;11(1):39. doi:[10.1186/1477-7827-11-39](https://doi.org/10.1186/1477-7827-11-39).
8. American Psychiatric Association. 5th ed. Washington: 2013.
9. Dutta S, Vankar GK. Delusions of pregnancy - a report of four cases. *Indian J Psychiatry*. 1996;38(4):254-256.
10. Michael A, Joseph A, Pallen A. Delusions of pregnancy. *Br J Psychiatry*. 1994;164(2):244-246. doi:[10.1192/bjp.164.2.244](https://doi.org/10.1192/bjp.164.2.244).