

An Unbelievable Foreign Body in a Maxillary Sinus

Alireza Ehsanbakhsh¹, Nasrin Khorashadizadeh¹, Amin Saburi^{2, 3, *}

¹ Radiology Department, Birjand University of Medical Sciences, Birjand, IR Iran

² Chemical Injuries Research Center, Baqiyatallah University of Medical Sciences, Tehran, IR Iran

³ Atherosclerosis and Coronary Artery Research Centre, Birjand University of Medical Sciences, Birjand, IR Iran

*Corresponding Author: Amin Saburi, MD, Chemical Injuries Research Center, Baqiyatallah University of Medical Sciences, Mollasadra st, Tehran, IR Iran. E-mail: aminsaburi@yahoo.com

Received: 29 Apr. 2016; Accepted: 23 Jun. 2016; Online Published: 27 Aug. 2016

Abstract

Introduction: Misdiagnosis and the resulting mismanagement are challenging issues in complicated cases which present with obscure complaints. Interpreting radiologic studies, especially conventional plain radiologic images, remains the most frequently prescribed and useful modality for the first step of assessment.

Case Presentation: In this report, we present a case of mismanagement of a strange foreign body in the maxillary sinus of a child not found in a facial x-ray.

Conclusion: Inexperienced non-radiologist physicians may make misdiagnoses when reading conventional x-rays.

Keywords: Foreign Body, Maxillary Sinus, Plain Radiograph, Radiologist

1. Introduction

There are many reports of foreign bodies (FB), most of which are strange and wonderful. Apart from foreign bodies reported after typical traumatic events, there are also other items commonly found in unusual places. The urethra, gastric cavity, esophagus, lungs, rectum, and abdominal cavity are the most common sites of FB described in previous reports [1-4]. Usual sites for FB include the parotid gland, joints, and intracranial cavity [5, 6]. Various reasons, including masturbation, child abuse, psychological disorders, and accidental presentation, have been mentioned for the presence of these FBs. Moreover, FBs differ widely; occasionally some of them are unbelievable and therefore remain undiagnosed. This is a report of a young girl who presented with complaints of prolonged rhinorrhea and facial tenderness due to a neglected FB after a penetrating facial trauma.

2. Case Presentation

A 12-year-old girl presented with a complaint of prolonged rhinorrhea and facial tenderness. The nasal discharge was unilateral and bloody. In her physical examination a mild fever was noted, but the nasal cavity examination did not show considerable abnormalities. She had a history of facial penetration by a pencil while playing with it about 4 weeks prior to this examination. At that time, she was examined by a young general physician in the emergency department (ED). The obtained skull X-ray was reported normal by the ED physician (Figure 1). After the initial exploration in the ED, the patient was discharged without further evaluation or radiologic studies. One month later, she returned with facial pain and tenderness in the right maxillary area in addition to nasal mucopurulent discharge.

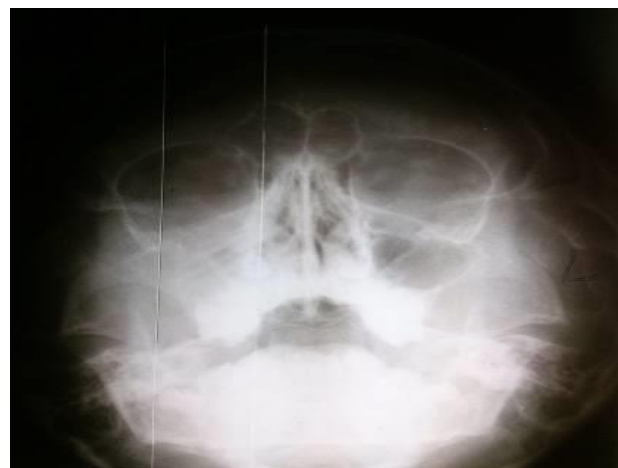

Figure 1. The plain x-ray demonstrating an opacity with a suspicious foreign body

Based on the history and examination, a CT scan was obtained for further assessment. A long tubular-shaped foreign body 60 mm in length was detected located in the patient's right maxillary sinus cavity with extension to the nasal cavity and cribriform plate. Moreover, soft tissue swelling in the right cheek and fluid accumulation in the maxillary and ethmoidal sinuses were noted. These findings were indicative of a missed penetrating broken pencil (Figure 2). Upon retrograde interpretation of the first skull x-ray, a linear opacity was noted in the mentioned area.

With the diagnosis of a FB remaining in the maxillary sinus, the patient underwent successful removal surgery during which a broken pencil with granulation tissue was found and excised (Figure 3). At the 2-week follow-up, the patient remained asymptomatic.

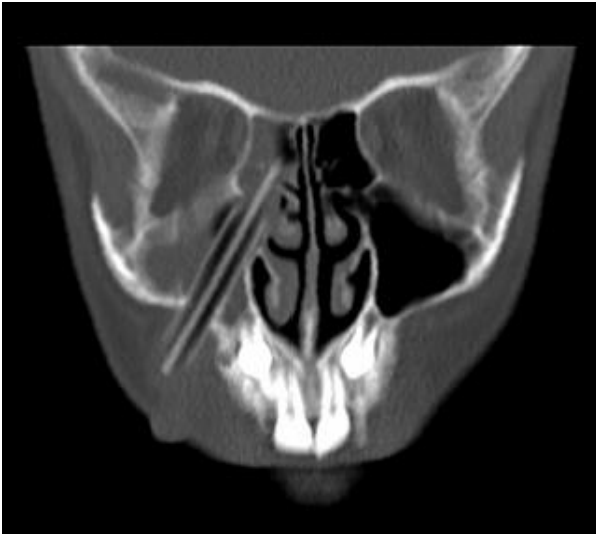


Figure 2. A tubular abnormality seen in CT scanning




Figure 3. A 5-cm broken pencil excised from the maxillary sinus

3. Discussion

There are some interesting points in this case report; imaging characteristics of FB, the role of the radiologist in interpreting doubtful cases, and complications caused by remaining and missed FBs (particularly pencils).

Although plain x-ray is the first imaging modality for evaluating suspicious FBs, a large number of FBs such as wood, glass, and plastic are radiolucent and not visible in plain x-rays [7, 8]. Therefore, other imaging modalities such as ultrasound or CT scanning are recommended in doubtful cases with negative x-ray for FBs.

In the presented case, the initial x-ray was considered normal by an ED physician, but in the retrograde interpretation, a tubular, abnormal opacity was seen. Therefore, consultation with radiologists can be helpful for inexpert physicians or in doubtful cases.

Furthermore, it has been previously reported that the core of a pencil can induce granuloma or granulosa sarcoma. A pencil core is made of carbon and various metal components such as aluminum which can induce soft tissue inflammation

and granuloma formation. Many reports recommend excising pencil cores as soon as they are diagnosed [6, 9].

4. Conclusion

Any FB found in an uncommon site of the human body, especially in children with no specific etiology such as gunshot, should be more carefully considered to prevent child abuse or other considerations of forensic medicine. Finally, exploration and precise examination using various imaging modalities and consultation with radiologists can help physicians manage suspicious cases.

Acknowledgements

The authors would like to thank the “Clinical Research Development Unit” of Baqiyatallah Hospital for their kind cooperation.

Authors’ Contributions

All authors contributed equally in the preparation of this paper.

Conflict of Interest

None.

References

- Bantis A, Sountoulides P, Kalaitzis C, Giannakopoulos S, Agelonidou E, Foutziti S, et al. Perforation of the urinary bladder caused by transurethral insertion of a pencil for the purpose of masturbation in a 29-year-old female. *Case Rep Med.* 2010;2010. pii: 460385. doi: [10.1155/2010/460385](https://doi.org/10.1155/2010/460385)
- Antao B, Foxall G, Guzik I, Vaughan R, Roberts J. Foreign body ingestion causing gastric and diaphragmatic perforation in a child. *Pediatr Surg Int.* 2005;21(4):326-8. doi: [10.1007/s00383-004-1347-8](https://doi.org/10.1007/s00383-004-1347-8)
- Byard RW, Eitzen D, James R. Unusual fatal mechanisms in nonasphyxial autoerotic death. *Am J Forensic Med Pathol.* 2000;21(1):65-8. doi: [10.1097/0000433-200003000-00012](https://doi.org/10.1097/0000433-200003000-00012)
- Singh RS, Dhaliwal R, Behera D. Unusual intrapulmonary foreign body: a pencil. *Indian J Chest Dis Allied Sci.* 1997;40(1):65-7.
- Kaiser M, Rodesch G, Capesius P. CT in a case of intracranial penetration of a pencil. *Neuroradiology.* 1983;24(4):229-31. doi: [10.1007/BF00399777](https://doi.org/10.1007/BF00399777)
- Kulkarni A, Mangham D, Davies AM, Grimer R, Carter S, Tillman R. Pencil-core granuloma of the distal radio-ulnar joint: an unusual presentation as soft-tissue sarcoma after 45 years. *J Bone Joint Surg Br.* 2003;85(5):736-8.
- Aras M, Miloglu O, Barutcuoglu C, Kantarci M, Ozcan E, Harorli A. Comparison of the sensitivity for detecting foreign bodies among conventional plain radiography, computed tomography and ultrasonography. *Dentomaxillofac Radiol.* 2014;39(2):72-8. doi: [10.1259/dmfr/68589458](https://doi.org/10.1259/dmfr/68589458)
- Turkcuer I, Atilla R, Topacoglu H, Yanturali S, Kiyani S, Kabakci N, et al. Do we really need plain and soft-tissue radiographies to detect radiolucent foreign bodies in the ED? *Am J Emerg Med.* 2006;24(7):763-8. doi: [10.1016/j.ajem.2006.03.013](https://doi.org/10.1016/j.ajem.2006.03.013)
- Yoshitatsu S, Takagi T. A Case of Giant Pencil-Core Granuloma. *J Dermatol.* 2000;27(5):329-32. doi: [10.1111/j.1346-8138.2000.tb02176.x](https://doi.org/10.1111/j.1346-8138.2000.tb02176.x)